

Fregoli syndrome in course of infection-related delirium. A case report

Sindrome di Fregoli in corso di delirium correlato a infezione. Un caso clinico

M. Salviati, C. Carlone, A. Provenzano, G. Valeriani, C. Melcore, F. Macrì, S. Terlizzi, M. Biondi

Department of Neurology and Psychiatry, Sapienza Università di Roma

Summary

Background

Fregoli syndrome is a rare clinical condition with a variable presentation: from a simple solitary psychiatric entity to an epiphenomenon of other mental disorders (most frequently schizophrenia). Occasionally, Fregoli syndrome may occur as a symptom that dominates the clinical history of organic diseases, which are often undiagnosed.

Clinical case

We report the clinical case of a woman who experienced delusional false recognition, meeting the criteria for Fregoli Syn-

drome, triggered by an acute pneumonia associated with urinary infection. This is an example of how an organic pathology can hide itself behind a psycho-pathological event.

Conclusions

According to our experience, it is important to manage this psychiatric disorder with correct differential diagnosis, especially in those cases in which the psycho-pharmacological treatment alone does not give satisfactory results in clinical improvement.

Key words

Fregoli • Misidentification • Urinary infections • Acute pneumonia

Introduction

The delusional false recognition includes a wide range of interconnected syndromes. Misidentification is explained by the concept of “the double”¹ and the belief that the identity of an object, a person or a place has been changed². Within this category, Capgras syndrome, Fregoli syndrome, syndrome of intermetamorphosis and syndrome of subjective doubles can be distinguished³.

There are also minor syndromes that are likewise considered as delusional misidentification syndromes (DMS): (i) mirrored self-misidentification⁴, in which the subject believes that his own reflection in the mirror belongs to another person; (ii) reduplicative paramnesia⁵, delusion that a person, a place, an object or a body was duplicated; (iii) syndrome of delusional companions⁶, characterized by the belief that inanimate objects (e.g. soft toys) are sentient beings; (iv) clonal pluralization of the self⁷, in which the subject believes in the existence of copies of itself, identical both physically and psychologically.

Capgras syndrome⁸, described for the first time in 1923 by the French psychiatrist Joseph Capgras⁹, is a rare condition in which the subject believes that a person, generally familiar with it, has been replaced by an exact copy. This specific identification mistake refers to sub-

jects linked to the patient by strong emotional ties, including ambivalence and conflict; these feelings would be strongly present at the time of onset^{10,11}.

The syndrome of intermetamorphosis¹² is based on the delusional belief that people, usually family members, exchanges identities with each other; in the most severe forms of this delusional misidentification syndrome the subject is too involved in his own delirium.

In the syndrome of subjective doubles¹³, the patient believes to be one of the doubles of himself, and for this reason thinks that its actions are independent from those of the other self. This delusional misidentification is accompanied by the idea that these duplicates are also equipped with a different psychological identity.

Fregoli syndrome, or illusion of the double, is a rare condition in which the individual (often characterized by paranoid traits) believes that different people are in fact a single person who changes appearance or is in disguise and, in some cases, is camouflaged in order to persecute the subject. People affected usually recognize strangers as if they were family, even if there is no physical resemblance. The term “Fregoli syndrome” was used for the first time in 1927 by Courbon and Fail, in honour of the Italian actor Leopoldo Fregoli, great imitator and transformist¹⁴.

Correspondence

Massimo Salviati, viale dell'Università 30, 00185 Roma, Italy • Tel./Fax +39 06 44362895 • E-mail: massimo_salviati@yahoo.it

The subject of false recognition (Table I) can be a human being or an inanimate object, has an important emotional bond (generally characterized by a conflict) with the affected person and is present at the time of onset¹⁵. Another element often found in the delusional patient is a feeling of ambivalence (characterized by the simultaneous presence of emotions such as hostility, fear, strife, and others like affection and dependence)¹⁶.

Inanimate objects are rarely the subject of false identification; when this happens the object in question seems to have an emotional value for the patient (e.g. a letter from a relative)¹⁷ (Table I).

Herein, we present the case of a 61-year-old woman, hospitalized in our Psychiatric Service for Diagnosis and Treatment (SPDC), with an acute psychopathological picture characterized by persecutory, bizarre and poorly structured delusion, compatible with the false recognition of Fregoli syndrome.

Case report

A 61-year-old woman was admitted to our department for an alteration of consciousness. At the first interviews the patient was disoriented in time, space and towards persons. She had rapid speech with increased productivity, tangential and derailing forms of thought, polarization on issues of persecution and paranoid delusional thinking. The patient demonstrated dysphoric mood, emotional lability, insomnia, false auditory perceptions

and motor hyperactivity. Clinical examination showed an altered interpretation of reality, due to the presence of the delusional state: the patient believed to be the centre of a conspiracy between an acquaintance and her employer who would be able to dress up and impersonate any person that came into contact with her. She identified her persecutor in all the healthcare staff, explaining how they were able to take on the appearance of other people, in order to persecute her, make her look insane and seize some of her ownership.

We evaluated the patient with the Brief Psychiatric Rating Scale (BPRS, Fig. 1)¹⁸, with a total score of 67 (critical items: suspiciousness, conceptual disorganization, disorientation, bizarre behaviour, unusual thought content), and with the Mini Mental State Examination (MMSE), with reported a score of 16.

The patient was treated with aripiprazole 20 mg/day and promazine 60 drops/day.

The clinical history of the woman, collected with the help of her family members, was negative for previous psychiatric disorders; the anamnesis showed diabetes mellitus type 2, complicated by peripheral neuropathy and retinopathy, treated with repaglinide and metformin (doses not specified). At routine analysis of blood and urine, tests for diabetes were added.

The results showed a significant elevation of inflammatory parameters: C-reactive protein 16400 mcg/l (NV 100-6000), ESR 62 mm/h (NV 0-35), neutrophilic leukocytosis with WBC 15700/mm³ (NV 4000-10000); white blood

TABELLA I.

Objects of false recognition, with the more associated clinical presentations. *Oggetti di falso riconoscimento, esempi in letteratura e manifestazioni cliniche correlate.*

Type of objects	Examples of literature	Syndromes
Partners in marriage	Clones, Lovers	Capgras' Syndrome, Reduplicative Paramnesia, Syndrome of Subjective Doubles, Syndrome of Intermetamorphosis, Fregoli's syndrome
Relatives	Sons, Parents, Brothers, Grandparents, Brothers In-laws, Cousins	Capgras' Syndrome, Reduplicative Paramnesia, Syndrome of Intermetamorphosis, Fregoli's syndrome
Other Figures	Boyfriends, Adoptive sons, Therapists, Neighbors, Domestics, Employers, Priests, Animals	Reduplicative Paramnesia, Syndrome of Intermetamorphosis, Fregoli's syndrome
Inanimate Objects	House, Letters from a Relative, Puppets, Dolls	Reduplicative Paramnesia, Syndrome of delusional companions
Oneself	Clones, Mirror's reflection	Mirrored Self Misidentification, Clonal Pluralization of the Self, Syndrome of Subjective Doubles

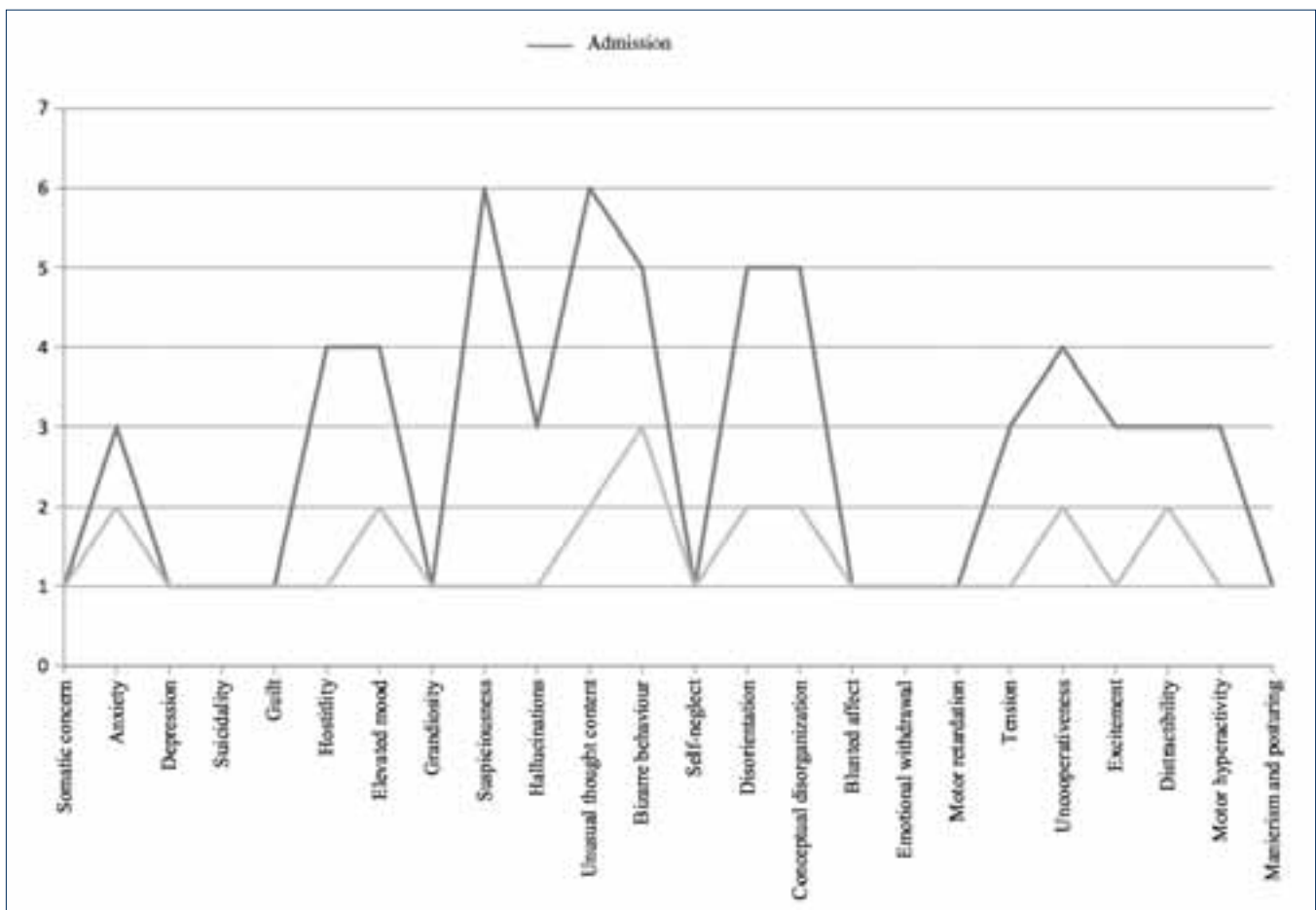


FIGURA 1.

BPRS variations in admission and at discharge. Each symptom is rated 1-7: 0 not evaluated; 1 absent; 2 very mild; 3 mild; 4 moderate; 5 moderately severe; 6 severe; 7 extremely severe. *Variazioni della scala BPRS all'ingresso e alla dimissione. Ogni sintomo è valutato secondo una scala 1-7; 0 non valutato; 1 assente; 2 molto lieve; 3 lieve; 4 moderato; 5 moderato severo; 6 severo; 7 estremamente severo.*

cell count: 2.4% lymphocytes (NV 19 to 48%), neutrophils 88.7% (NV 40-74%); glycosylated haemoglobin of 4.8 mg/dl and normal blood glucose level.

At physical examination the patient showed bilateral pain at urethral points, had pathological sounds at the right lung base and the body temperature was 37.8°C. Chest X-ray showed a parenchymal thickening at the right lung base, with increased vascular pattern at the level of the hilum bilaterally, associated with a hypo-expanded left costophrenic angle.

According with all these findings, the consultant infectivistologist made a diagnosis of acute pneumonia, and the patient underwent antibiotic treatment with ceftriaxone 2 g iv/day and clarithromycin 500 mg 2 tablets/day for one week. Legionella antigen was tested in the patient's urine. After two days of hospitalization, the patient was still confused, disoriented, showed incongruous behaviour,

had an important and bilateral index-nose dysmetria and her ability to maintain the lower limbs raised was only 30 sec.

Neurological examination ruled out any neurological disease as a cause of the symptoms described. The consultant neurologist recommended a further study with electroencephalogram (EEG) and a brain contrast-enhanced MRI. The video-EEG of the patient was normal. MRI showed a chronic subcortical encephalopathy, due to ischaemic vascular disease; the FLAIR sequences discovered many areas of hyperintensity (about a cm in diameter) bilaterally spread in the periventricular and subcortical white matter; no pathological focal enhancement was found after intravenous contrast administration.

On the fourth day of treatment the patient still showed no improvement, and symptoms had worsened and she

became increasingly suspicious because of her delusional false recognitions. Suspecting an organic cause as the trigger for symptoms, we inserted a catheter to study the urinary tract. Urine collection was frankly purulent.

The infectious-disease specialist confirmed current antibiotic therapy and recommended implementation with renal ultrasound that showed ectasia of the lower caliceal group in the left kidney.

Urinary Legionella antigen was negative, but cultural examination of urine showed the presence of abundant and mixed microbial flora.

With the improvement of infection (due to antibiotic therapy and purulent urine excretion), we also observed rapid improvement of psychiatric symptoms: after a few days of antibiotic treatment the patient appeared euthymic, cooperative and well oriented, without confusion episodes. We also observed recovery of psycho-motor skills, remission of content and formal thought disorders and the absence of false psycho-sensorial perceptions.

On the ninth day of treatment, we obtained remission of false recognitions, with improvement of the perception of reality (which no longer seemed hostile and persecutory). After two weeks of hospitalization blood tests were normal, urethral pain and fever had disappeared, and it was decided to discontinue antibiotic therapy and remove the catheter.

Physical examination of the lung was negative.

Administering the BPRS control scale (Fig. 1), we recorded a total score of 32 (with no critical items).

The patient was also subjected to neuropsychological investigation to study cognitive functions¹⁹. The results showed a mild cognitive impairment (Fig. 2), compatible with the pathological findings observed with MRI.

The MMSE administered at discharge reported a score of 23.5 (MMSE score at admission: 16).

On the twelfth day of hospitalization, we began to reduce antipsychotic therapy, observing a stable remission of psycho-pathological disorders. After a further eight days the patient was discharged.

TEST	Weighted Score	Cut-off
Mini Mental State Examination	23,53	≥ 23,85
Rey's 15 Words-IR	15,6	≥ 28,53
Learning Curve	4-1-5-4-2	
Rey's 15 Words-DR	1	≥ 4,69
Recognition	67 %	> 88 %
Prose Memory	7,3	12,98 ± 2,08
Immediate Visive Memory	14,4	≥ 13,85
Ideomotor Praxia	20	20
Bucco-Facial Praxia	20	20
Drawings Copying without program's elements	5,6	≥ 7,18
Drawings Copying with program's elements	60,5	≥ 61,85
Raven's Matrices 47	16,8	≥ 18,96
Digit Span Forward	4,75	≥ 3,75
Digit Span Backward	3	
Spatial Span Forward	4	≥ 3,5
Spatial Span Backward	2	
Semantic Verbal Fluency	14	33,88 ± 8,13
Phonological Verbal Fluency	15,3	≥ 17,35
Attentive Matrices	17,5	≥ 31
Trail Making Test A	300"	≤ 94"
Trail Making Test B	---	≤ 283"
Aachener Aphasia Test	9	> 8

FIGURA 2

Neuropsychological Tests. *Test neuropsicologici.*

Conclusions

Fregoli syndrome is a rare clinical condition with a variable presentation: from a simple solitary psychiatric entity to an epiphenomenon of other mental disorders. Occasionally, Fregoli syndrome may occur as a symptom that dominates the clinical history of general medical conditions, which are not infrequently undiagnosed.

The case herein reported is an example of how an infective state can hide itself behind a psycho-pathological event. The patient had no previous psychiatric disorders; she had a history of type 2 diabetes, in good clinical and metabolic compensation; moreover, her mild cognitive impairment (based on cerebrovascular disease and confirmed by imaging studies and neuro-psychological tests) was asymptomatic. In this case, an acute pneumonia associated with a urinary infection triggered a delusional false recognition.

In the scientific literature there is only one report of Fregoli syndrome due to an infective event: a case of typhoid infection²⁰. However, considering the broader category of Delusional Misidentification Syndromes (DMS) there is an extensive literature that divides the causes as psychiatric and related to general medical conditions²¹⁻²⁶.

In particular, in Berson's study¹⁰ on 133 patients with DMS, 63% of subjects were affected by schizophrenia, 13% had a manic-depressive illness and 24% had a mental disorder due to a general medical condition.

Considering patients with schizophrenia or bipolar disorder, several theories could explain these delusions, such as right temporolimbic-frontal disconnection²⁷, interhemispheric disconnection of cortical areas²⁸, and cognitive theories such as "face recognition defect" in schizophrenia²⁹.

The first³⁰ hypothesizes that a volume loss concentrated in the right frontotemporal region, and the subsequent right temporolimbic-frontal disconnection, results in impossibility to associate previous memories with new information, and consequently misidentifying symptoms. However, regarding Fregoli syndrome, Ramachandran et al. suggested that this disorder may occur when the temporal-limbic connection becomes hyperactive, rather than disconnected³¹.

The second hypothesis implies a dysfunctional connection between occipito-temporal regions and areas of prefrontal cortex via the uncinate fasciculus and limbic-thalamic³².

The latest theory is about the cognitive characteristics of schizophrenic patients, also known as "jumping-to-conclusions"³³: this cognitive style induces patients to draw conclusions about face recognition from inadequate evidences.

Regarding the 24% of patients who present Fregoli syndrome in relation to general medical conditions, most of

the cases reported in the literature show that it develops during a state of altered consciousness. Among other medical situations, infective diseases are prone to elicit mental confusion and delirium. This condition is particularly associated with a central cholinergic dysfunction and an imbalance between proinflammatory and antiinflammatory factors, in favour of a proinflammatory response³⁴. According to recent observations, at the peripheral level, the cholinergic anti-inflammatory pathway modulates the immune system through the interaction of acetylcholine (ACh) with immune cells. In baseline conditions, ACh availability depends on vagus nerve output and its degradation by cholinesterases (ChE). In patients with delirium, exposure to severe infectious states induce different degrees of inflammation according to the baseline status of the peripheral ChE activity, suggesting that delirium is associated with an overactive relation between cholinergic and inflammatory systems. Unfortunately, there is a lack of studies that have investigated the correlation between blood chemistry parameters of inflammation and neuroimaging data found in the course of misidentification syndromes. A case report of Crichton and Lewis³⁵ described a right parietal lesion during serial CT scanning in a patient with Capgras syndrome during a delirium caused by an opportunistic AIDS-related infection; however, further studies are needed.

According to our experience, it is important to manage this psychiatric disorder with correct differential diagnosis, especially in cases with negative psychiatric history and acute onset of delusional symptoms, in which psycho-pharmacological treatment alone does not give satisfactory results in the improvement of clinical conditions. However, further studies are needed to elucidate and better understand this uncommon condition.

References

- Oyebode F, Sargeant R. *Delusional misidentification syndromes: a descriptive study*. Psychopathology 1996;29:209-14.
- Ellis HD, Young AW. *Accounting for delusional misidentifications*. Br J Psychiatry 1990;157:239-48.
- Ellis HD, Luauté JP, Retterstøl N. *Delusional misidentification syndromes*. Psychopathology 1994;27:117-20.
- Villarejo A, Martin VP, Moreno-Ramos T, et al. *Mirrored-self misidentification in a patient without dementia: evidence for right hemispheric and bifrontal damage*. Neurocase 2011;17:276-84.
- Lee K, Shinbo M, Kanai H, et al. *Reduplicative paramnesia after a right frontal lesion*. Cogn Behav Neurol 2011;24:35-9.
- Shanks MF, Venneri A. *The emergence of delusional companions in Alzheimer's disease: an unusual misidentification syndrome*. Cogn Neuropsychiatry 2002;7:317-28.
- Ranjan S, Chandra PS, Gupta AK, et al. *Clonal plu-*

- ralization of self, relatives and others. *Psychopathology* 2007;40:465-7.
- 8 Enoch MD. *The Capgras Syndrome*. *Acta Psychiatr Scand* 1963;39:437-62.
- 9 Capgras J, Reboul-Lachaux J. *Illusion des sosies dans un délire systématisé chronique*. *Bulletin de la Société Clinique de Médecine Mentale* 1923;2:6-16.
- 10 Berson RJ. *Capgras' syndrome*. *Am J Psychiatry* 1983;140:969-78.
- 11 Christodoulou GN. *The syndrome of Capgras*. *Br J Psychiatry* 1977;130:556-64.
- 12 Courbon P, Tusques J. *Illusions d'intermétamorphose et de charme*. *Ann Médico Psychol* 1932;90:401-5.
- 13 Christodoulou GN. *Syndrome of subjective doubles*. *Am J Psychiatry* 1978;135:249-51.
- 14 Courbon P, Fail G. *Syndrome d'illusion de Frégoli et schizophrénie*. *Bulletin de la Société Clinique de Médecine Mentale* 1927;15:121-5.
- 15 Enoch MD. *Whose double? The psychopathology of the delusional misidentification syndromes, especially the Capgras syndrome*. *Bibl Psychiatr* 1986;(164):22-9.
- 16 Edelstyn NM, Oyebode F. *A review of the phenomenology and cognitive neuropsychological origins of the Capgras syndrome*. *Int J Geriatr Psychiatry* 1999;14:48-59.
- 17 Ellis HD, Quayle AH, de Pauw KW, et al. *Delusional misidentification of inanimate objects: a literature review and neuropsychological analysis of cognitive deficits in two cases*. *Cogn Neuropsychiatry* 1996;1:27-40.
- 18 Overall JE, Gorham DR. *The brief psychiatric rating scale*. *Psychological Reports* 1962;10:799-812.
- 19 Woodford HJ, George J. *Cognitive assessment in the elderly: a review of clinical methods*. *QJM* 2007;100:469-84.
- 20 Stanley PC, Andrew AE. *Fregoli syndrome: a rare persecutory delusion in a 17 year old sufferer of psychosis associated with typhoid fever at Jos University Teaching Hospital, Jos, Nigeria*. *Niger J Med* 2002;11:33-4.
- 21 Christodoulou GN, Margariti M, Kontaxakis VP, et al. *The delusional misidentification syndromes: strange, fascinating, and instructive*. *Curr Psychiatry Rep* 2009;11:185-9.
- 22 Christodoulou GN. *Delusional hyper-identifications of the Frégoli type. Organic pathogenetic contributors*. *Acta Psychiatr Scand* 1976;54:305-14.
- 23 MacCallum WA. *The interplay of organic and psychological factors in the delusional misidentification syndromes*. *Bibl Psychiatr* 1986;(164):92-8.
- 24 Madoz-Gúrpide A, Hillers-Rodríguez R. *Capgras delusion: a review of aetiological theories*. *Rev Neurol* 2010;50:420-30.
- 25 Mojtabai R. *Fregoli syndrome*. *Aust N Z J Psychiatry* 1994;28:458-62.
- 26 Roane DM, Rogers JD, Robinson JH, et al. *Delusional misidentification in association with parkinsonism*. *J Neuropsychiatry Clin Neurosci* 1998;10:194-8.
- 27 Ramachandran VS, Blakeslee S. *Phantoms in the brain: Probing the mysteries of the human mind*. New York: William Morrow 1998.
- 28 Feinberg TE, Eaton LA, Roane DM, et al. *Multiple fregoli delusions after traumatic brain injury*. *Cortex* 1999;35:373-87.
- 29 Hooker C, Park S. *Emotion processing and its relationship to social functioning in schizophrenia patients*. *Psychiatry Res* 2002;112:41-50.
- 30 Feinberg TE, Roane DM. *Delusional misidentification*. *Psychiatr Clin N Am* 2005;28:665-83.
- 31 Hirstein W, Ramachandran VS. *Capgras syndrome: a novel probe for understanding the neural representation of the identity and familiarity of persons*. *Proc R Soc Lond B Biol Sci* 1997;264:437-44.
- 32 Edelstyn NMJ, Oyebode F, Barrett K. *The delusions of Capgras and intermetamorphosis in a patient with right-hemisphere white-matter pathology*. *Psychopathology* 2001;34:299-304.
- 33 Moritz S, Woodward TS, Hausmann D. *Incautious Reasoning as a pathogenetic factor for the development of psychotic symptoms in schizophrenia*. *Schizophr Bull* 2006;32:327-31.
- 34 Cerejeira J, Nogueira V, Luís P, et al. *The Cholinergic System and Inflammation: Common Pathways in Delirium Pathophysiology*. *JAGS* 2012;60:669-75.
- 35 Crichton P, Lewis S. *Delusional misidentification, AIDS and the right hemisphere*. *Br J Psychiatry* 1990;157:608-10.